

Restoring Esthetics with Metal-Free Ceramics: A Case Report

Sandeep Walia, DDS; Praveen M. Joseph Thomas, DDS; Harinder Sandhu, DDS, PhD;
Gildo Coelho Santos Jr., DDS, MSc, PhD

“Clinical Showcase” is a series of pictorial essays that focus on the technical art of clinical dentistry. The section features step-by-step case demonstrations of clinical problems encountered in dental practice. If you would like to contribute to this section, contact editor-in-chief Dr. John O’Keefe at jokeefe@cda-adc.ca.

Metal-ceramic systems represent a high-strength treatment associated with long-term success, but they have several disadvantages, mainly in terms of esthetics and biocompatibility. Over the past decade, a number of novel all-ceramic crown and bridge systems have been developed, with the capability of restoring anterior, posterior and multiple units. The search for new methods has been driven, in part, by patients, who have increasingly high expectations of esthetic dentistry and who also have concerns about the intraoral biocompatibility of metals.¹

Recent developments in dental materials have led to the introduction of a large number of all-ceramic systems for full-coverage restorations. Some systems use a single-layer glass-ceramic material (e.g., Dicsply/Caulk; IPS Empress, Ivoclar/Vivadent), whereas others have a dual-layer design (In-Ceram, Vident; Procera, Nobel Biocare).² Further improvements in high-strength all-ceramic technology have been achieved with the advent of computer-aided design and milling (CAD/CAM) systems. The Procera system first introduced in 1993 is one example.³ This type of all-ceramic crown resists fracture during function or parafunction, at both anterior and posterior sites, even under high stresses.⁴

The design and manufacture of these restorations involves optical scanning and digitizing of the dies (which are created from a master impression of the prepared teeth and cores), to precisely duplicate the margins of the tooth preparation. The scanned 3-dimensional images of the dies are then used to design the substructure, prompted by computer software (CAD). The CAD unit is linked to a robotic CAM

centre, which creates a ceramic coping to the design specifications.¹

Clinical evaluations of all-ceramic crowns have been promising, and a success rate of 98.4% over a period of 2–3.5 years has been reported.³ Recently, Haselton and colleagues⁴ reported 100% satisfaction among patients treated with all-ceramic crowns. The following report describes the restoration of 4 maxillary incisors with the Procera all-ceramic system.

Case Report

A 28-year-old woman in excellent health was referred because of the appearance of her maxillary anterior teeth, which had been restored with full gold crowns (Fig. 1). During the treatment planning session, the patient was given the option of porcelain-fused-to-metal or metal-free restorations. The patient chose to have all of the teeth restored with the Procera Alumina system.

Occlusion was analyzed preoperatively, both clinically and with the aid of mounted study models on a semi-adjustable articulator. A diagnostic wax-up was completed and modified at chairside with the patient’s input, until the final form of the new restorations was deemed esthetically satisfactory.

At the stage of tooth preparation and registration, all of the gold crowns were cut using a long, thin diamond bur. The abutment teeth were refined using modified shoulder diamond burs (coarse and superfine) before an impression was taken for laboratory-made provisional restorations (Fig. 2). The patient was sent home with chairside provisional restorations made from a bis-acryl material (Integrity, Dentsply/Caulk, Konstanz, Germany), cemented with non-eugenol temporary

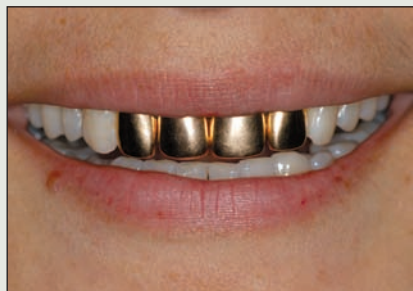

Figure 1: Maxillary anterior teeth of a 28-year-old woman with full gold crowns.

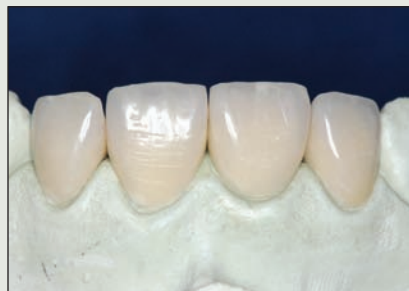


Figure 2: Provisional restorations made in the laboratory.

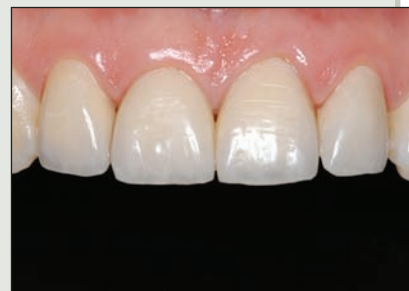

Figure 3: Facial view of the patient after insertion of provisional restorations. Teeth 11 and 21 exhibit a discrepancy of the gingival line.

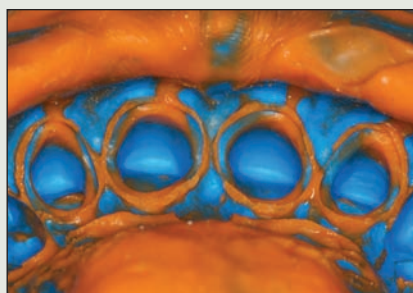


Figure 4: Impression made from silicon impression material. The modified shoulder finish line is required for all-ceramic crowns.

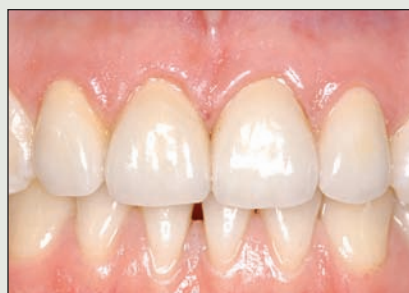

Figure 5: Close-up view of the 4 Procera AllCeram crowns after cementation.

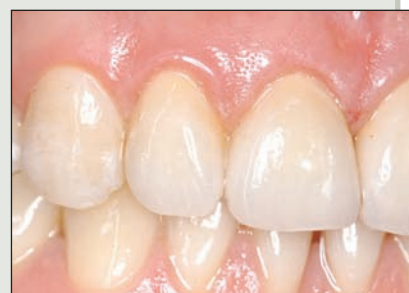

Figure 6: Intraoral facial view of teeth 11 and 12.

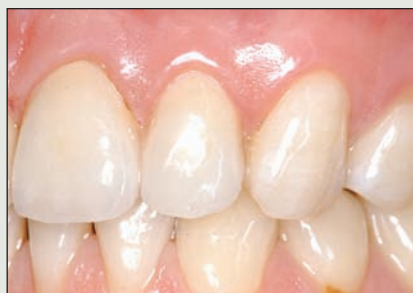

Figure 7: Intraoral facial view of teeth 21 and 22.

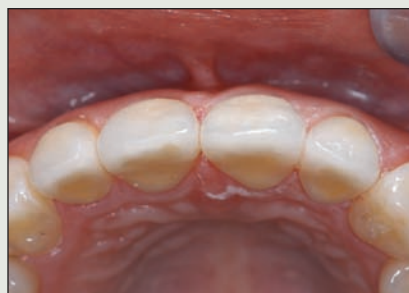

Figure 8: Lingual view of the maxillary anterior teeth.

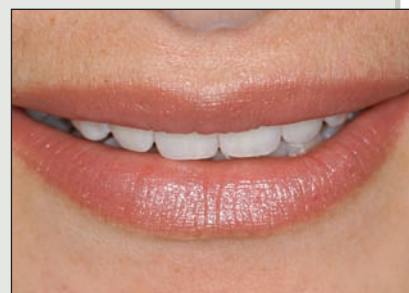

Figure 9: Final result. There is excellent colour-matching with the rest of the teeth and superior lifelike esthetics.

cement (TempBond NE, Kerr, Romulus, Mich.). Upon completion of the provisional treatment stage, the patient underwent periodontal therapy to correct the gingival line and to ensure even crown length and gingival margins of the 2 central incisors (Fig. 3)

When the patient returned for final placement, the provisional restorations were removed, and the preparation on tooth 21 was refined. After the margins were refinished, a small unimpregnated retraction cord was placed (Ultrapack #000, Ultradent,

South Jordan, Utah), followed by a second cord (Ultrapack #00, Ultradent) impregnated with hemostatic solution (Hemodent, Ultradent). The final full-arch impression was made with a combination of heavy- and light-viscosity polyvinyl siloxane (Take 1, Kerr) (Fig. 4). An impression of the opposing dentition was also made with irreversible hydrocolloid (Jeltrate, Dentsply/Caulk). An interocclusal record at maximum intercuspitation and a face bow transfer were obtained. The shade was determined with a shade guide (Vitapan 3D Master,

Vita, Bad Säckingen, Germany). The Procera crowns were manufactured at Dental Design Centre (DDC, London, Ont.).

During the final appointment, all abutment teeth were cleaned of temporary cement, and all restorations were cemented with a reinforced glass ionomer luting cement (GC Fuji Plus, GC, Alsip, Ill.) (Figs. 5–9). The patient received postoperative care instructions, and recall appointments were scheduled.

Discussion

All-ceramic systems offer a promising alternative for the restoration of anterior teeth, and short-term clinical evaluations have demonstrated high success rates.^{5,6} The Procera system is a CAD/CAM system for the creation of anterior and posterior crowns and fixed partial dentures. Fabrication of an alumina coping requires scanning the die, designing the substructure with the computer aid, milling the 99.5% pure aluminum oxide (Al₂O₃) block and sintering. According to the manufacturer, the substructure has a fracture resistance of about 680 MPa. It is veneered with compatible feldspathic porcelain to achieve the desired contour and esthetics.² The marginal gaps of Procera crowns are within the range of clinical acceptance, from 36 µm to 83 µm.⁷ Because the fitted surface of the aluminum oxide coping is microscopically rough, there is little to be gained by acid-etching; surface treatment of the fitted surface is therefore usually restricted to sandblasting and application of a saline-coupling agent. A translucent composite cement such as Panavia 21 TC (J. Morita) has been suggested as the cement of choice, yielding impressive esthetic results. This product is supplied with a priming agent, and coupling with a total etch procedure is recommended.⁸ Glass ionomer cement has been advocated for use in cases of suboptimal moisture control. This material has been shown to transmit light somewhat more readily.⁶

Reports from in vitro studies and some clinical trials indicate that the Procera system holds great promise. It yields high-strength copings with veneering ceramics of excellent esthetic value. Given the metal-free nature of the prosthesis, the incidence of allergic reactions among patients is likely to be lower than with metal prostheses.^{1,6}

Conclusions

The short-term results achieved in this case indicate the potential value of the Procera system in creating restorations with excellent marginal fit

and esthetics. However, further long-term clinical data will be required to support this preliminary conclusion. ✦

THE AUTHORS



Dr. Walia is in private practice in Toronto, Ontario.



Dr. Joseph Thomas is in private practice in Mississauga, Ontario.



Dr. Sandhu is a professor of periodontics and director, Schulich Dentistry, Schulich School of Medicine & Dentistry, The University of Western Ontario, London, Ontario.



Dr. Santos Jr. is an assistant professor of restorative dentistry, Schulich School of Medicine & Dentistry, The University of Western Ontario, London, Ontario.

Acknowledgements: We would like to thank Dr. Munir El-Kassem for his assistance with the selection of the patient, and Meghan Perinpanayagam for her assistance with the preparation of this manuscript.

Correspondence to: Dr. Gildo C. Santos Jr., The University of Western Ontario, Schulich School of Medicine & Dentistry, Dental Sciences Building, Room 0147, London, ON N6A 5C1. Email: gildo.santos@schulich.uwo.ca

The authors have no declared financial interests in any company manufacturing the types of products mentioned in this article.

References

1. Barnfather KD, Brunton PA. Restoration of the upper dental arch using Lava all-ceramic crown and bridgework. *Br Dent J* 2007; 202(12):731–5.
2. Polack MA. Restoration of maxillary incisors with a zirconia all-ceramic system: a case report. *Quintessence Int* 2006; 37(5):375–80.
3. Zitzmann NU, Galindo ML, Hagmann E, Marinello CP. Clinical evaluation of Procera AllCeram crowns in the anterior and posterior regions. *Int J Prosthodont* 2007; 20(3):239–41.
4. Haselton DR, Diaz-Arnold AM, Hillis SL. Clinical assessment of high-strength all-ceramic crowns. *J Prosthet Dent* 2000; 83(4):396–401.
5. Lopes GC, Baratieri LN, Caldeira de Andrada MA, Maia HP. All-ceramic post core, and crown: technique and case report. *J Esthet Restor Dent* 2001; 13(5):285–95.
6. Oden A, Andersson M, Krystek-Ondracek I, Magnusson D. Five-year clinical evaluation of Procera AllCeram crowns. *J Prosthet Dent* 1998; 80(4):450–6.
7. Kokubo Y, Ohkubo C, Tsumita M, Miyashita A, Vult von Steyern P, Fukushima S. Clinical marginal and internal gaps of Procera AllCeram crowns. *J Oral Rehabil* 2005; 32(7):526–30.
8. Sieber C. A key to enhancing natural esthetics in anterior restorations: the light-optical behavior of Spinell luminaries. *J Esthet Dent* 1996; 8(3):101–6.